

# Apotemnophilia: a neurological disorder

David Brang, Paul D. McGeoch and Vilayanur S. Ramachandran

Center for Brain and Cognition, University of California, San Diego, La Jolla, California, USA

Correspondence to David Brang, 9500 Gilman Drive, San Diego, La Jolla, CA 92093-0109, USA  
Tel: +1 858 534 7907; fax: +1 858 534 7190; e-mail: dbrang@ucsd.edu

Received 24 May 2008; accepted 29 May 2008

DOI: 10.1097/WNR.0b013e32830abc4d

Apotemnophilia, a disorder that blurs the distinction between neurology and psychiatry, is characterized by the intense and long-standing desire for amputation of a specific limb. Here we present evidence from two individuals suggestive that this condition, long thought to be entirely psychological in origin, actually has a neurological basis. We found heightened skin conductance response

to pinprick below the desired line of amputation. We propose apotemnophilia arises from congenital dysfunction of the right superior parietal lobule and its connection with the insula. *NeuroReport* 19:1305–1306 © 2008 Wolters Kluwer Health | Lippincott Williams & Wilkins.

**Keywords:** amputee, body image, body integrity image disorder, neurology

## Introduction

Disorders that straddle the boundary between neurology and psychiatry are of special interest to scholars in both disciplines. One example is apotemnophilia or body integrity image disorder [1–3]. In this disorder, otherwise sane and rational individuals express a strong and specific desire for the amputation of a healthy limb or limbs. Most date this desire to their childhood and not uncommonly the sufferer will attempt to obtain amputation of the specific limb. As few surgeons are willing to amputate healthy limbs, this often means that the patient themselves will attempt to irrevocably damage the limb in question, thus necessitating formal amputation. After amputation most report to being happy with their decision and often state, paradoxically, that they are ‘complete’ at last [2,3].

The disorder has long been regarded as being purely psychological in origin [1–3]. It has been argued that it might be a ‘cry for attention’ or a sexual paraphilia [1], although why it should take this particular form is not clear. Others have proposed that seeing an amputee at a young age has caused this to be somehow ‘imprinted’ onto the sufferer’s psyche as the ‘ideal body image’ [4]. Bizarrely, it has even been suggested that the supposed phallic resemblance of an amputee’s stump is the underlying motivator [5,6].

We were struck by certain striking parallels [7] between apotemnophilia and the neurological syndrome of somatoparaphrenia, that can follow damage to the right parietal lobe, particularly the right superior parietal lobule, which is known to be vital in constructing one’s body image [8]. In somatoparaphrenia, the patient vehemently denies ownership of his left arm or leg, often attributing it to the examining physician or a spouse or sibling who may not even be in the vicinity. In these cases the patient sometimes develops an actual aversion to the limb saying things like ‘It’s a communist’ or ‘It’s hideous’.

We proposed that apotemnophilia, like somatoparaphrenia, is caused by dysfunction of the right parietal lobe leading to a distorted body image and a desire for an amputation of one or more limbs [8]. This neurological, as opposed to psychodynamic, view of apotemnophilia is supported by four observations. i) The fact that the desire for amputation is almost three times more common for the left leg as for the right leg alone and we see no reason to expect such an asymmetry if the disorder was psychological [2]. ii) The similarity, as already alluded to, between it and somatoparaphrenia. iii) That the patient is usually able to trace out the precise line on the limb along which the amputation is desired – a line that typically remains stable over time [2]. iv) Finally, as with somatoparaphrenia, some patients find ownership of the limb to be vaguely aversive; hence the desire to be rid of it.

## Methods

We tested our conjecture on two individuals with apotemnophilia by measuring skin conductance response (SCR) to pinprick above and below the line of desired amputation on each leg. Ethical approval from the local institutional review board and signed consent from the patients was obtained.

Two patients were recruited: A.O. is a 29-year-old man who desires a right below knee amputation and B.C. is a 63-year-old man and desires amputations both below his left knee and below his right thigh. Both are right-handed and dated their desire for an amputation to early childhood. The past medical history of both patients was otherwise unremarkable and a neurological examination was normal. A mini mental examination was administered and they were emotionally and intellectually normal as judged by their ability to interact and converse appropriately.

SCR was measured with a pair of Ag–AgCl electrodes attached to the palmar surface of the index and middle fingers on the right hand. We examined response to pinprick at four sites: both feet, and both upper thighs above the desired line of amputation. The patients had their eyes closed throughout the procedure and pinprick was applied in a random order to the four sites. The examiner was blind as to which leg (and level) the patient desired to be amputated and was careful to evenly apply pressure when carrying out the stimulations. An identical method was then employed on five control participants.

## Results

The results were clearcut (Fig. 1). In A.O. there was a two-fold difference in SCR between the left and right legs below the line of amputation [ $F(1,74)=7.88$ ,  $P<0.01$ ]. A two-fold difference across the desired line of amputation on the right leg [ $F(1,67)=10.16$ ,  $P<0.005$ ] but no difference across an equivalent virtual line on the normal limb [ $F(1,65)=0.288$ ,  $P=NS$ ] was also observed. In B.C., who wanted both legs amputated, recorded differences were more striking. Across the line of amputation in both the left and right legs, there was a three-fold difference below the line of amputation compared to above it [left leg  $F(1,35)=19.58$ ,  $P<0.001$ ; right leg  $F(1,35)=20.43$ ,  $P<0.001$ ]. No significant difference between the legs [ $F(1,72)=0.10$ ,  $P=NS$ ] was observed. No differences were observed in the control group either between the foot and thigh [left leg  $F(1,110)=2.48$ ,  $P=NS$ ; right leg  $F(1,114)=1.86$ ,  $P=NS$ ], or between the legs [ $F(1,226)=0.04$ ,  $P=NS$ ].

## Discussion

We believe these findings provide psychophysiological evidence to support our hypothesis that apotemnophilia arises from a congenital dysfunction of the right parietal lobe and, in particular the right superior parietal lobule, which receives and integrates input from various sensory areas and the insula to form a coherent sense of body image [7,9,10]. Skin conductance, which is not thought to be under volitional control, is an indicator of general sympathetic arousal [11]. It is mediated by right forebrain structures, especially the insula, that are involved in exerting control of the sympathetic nervous system [11,12]. We propose that the

failure of a congenitally dysfunctional right superior parietal lobule to form an unified body image leads to abnormal sympathetic outflow via the insula; manifesting itself as the observed SCR changes. The syndrome lends itself to functional brain imaging studies, which we are currently conducting.

When this dysfunction is acquired, as in somatoparaphrenia, the brain seems sometimes to rationalize the discrepancy by denying ownership of the limb. When the dysfunction is congenital it leads to a feeling that affected area should not be there to begin with and a desire for an amputation. This fits in with the report from both patients that the desire had started as a young child. The specific locus of desired amputation may depend on the exact location of the altered connections between the right superior parietal lobule and the primary and secondary somatosensory cortices, or its projections to limbic structures such as the insula. What is critical is the fact that somatosensory input from the limb to S1 is intact whereas the body image is missing the leg. We suggest that it is this discrepancy that leads to the aversion and desire for amputation. We have seen some preliminary hints – using Magnetoencephalography – that this may be a right superior parietal lobule dysfunction in these patients, with some additional abnormal ipsilateral activation.

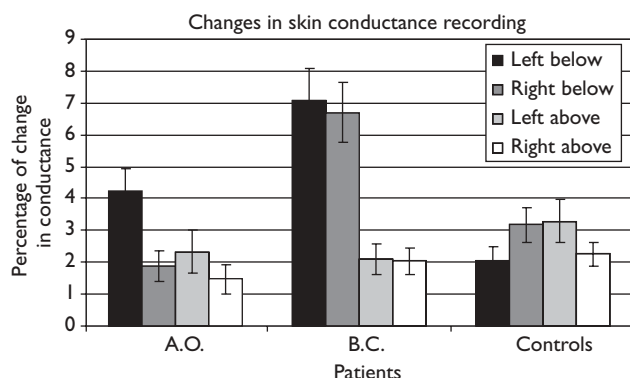
Clearly investigations into apotemnophilia are not merely relevant to people with the condition but also have the potential to tell us about how the normally functioning brain creates the sense of body image. Moreover, exploring such curious conditions that stand in the hinterland between neurology and psychiatry may provide key insights into the question of how neural activity gives rise to mental phenomena.

## Acknowledgements

The authors thank Toby MacDonald, Helen Crocombe, and Robert Vickers for their help. Dick Geckler, Herb Lurie and C. Robbins partially funded this project. They had no role in its conception or design. All authors declare that the answer to the questions on your competing interest form are all No and therefore have nothing to declare.

## References

1. Money J, Jobaris R, Furth G. Apotemnophilia: two cases of self-demand amputation as a paraphilia. *J Sex Res* 1977; **13**:115–125.
2. First M. Desire for an amputation of a limb: paraphilia, psychosis, or a new type of identity disorder. *Psychol Med* 2005; **35**:919–928.
3. Bayne T, Levy N. Amputees by choice: body integrity identity disorder and the ethics of amputation. *J Appl Philos* 2005; **22**:75–86.
4. Reference: Body Integrity Identity Disorder (Accessed 12th March 2008 at <http://www.reference.com/search?q=apotemnophilia>).
5. Fleischl MF. A man's fantasy of a crippled girl. *Am J Psychother* 1960; **14**:471–748.
6. Wakefield PL, Frank A, Meyers RW. The hobbyist: a euphemism for self-mutilation and fetishism. *Bull Menninger Clin* 1977; **41**:539–552.
7. Critchley M. *The parietal lobes*. 1st ed. New York, United States: Hafner Publishing Company; 1953. pp. 225–255.
8. Ramachandran VS, McGeoch PD. Can vestibular caloric stimulation be used to treat apotemnophilia? *Med Hypotheses* 2007; **69**:250–252.
9. Har R, Forss N. Magnetoencephalography in the study of human somatosensory cortical processing. *Phil Trans R Soc Lond B* 1999; **354**:1145–1154.
10. Felleman DJ, Van Essen DC. Distributed hierarchical processing in the primate cerebral cortex. *Cereb Cortex* 1991; **1**:1–47.
11. Critchley HD. Electrodermal responses: what happens in the brain. *Neuroscientist* 2002; **8**:132–142.
12. Oppenheimer SM, Gelb A, Girvin JP, Hachinski VC. Cardiovascular effects of human insular cortex stimulation. *Neurology* 1992; **42**:1727–1732.



**Fig. 1** Changes in skin conductance recording in response to pinprick above and below desired levels of amputation in the legs. A.O. desired a left leg amputation only, and B.C. wanted both legs amputated. Both individuals with apotemnophilia showed significant increases below the line of amputation.